

Table 1: Under general and infectious category

| Name | Description/location/size | LM/EM | Stains/markers | Observed in/significance |
|-----------------|---|----------------------------|---|--|
| Langerhans cell | Named after Paul Langerhans. Is a pale-staining non-keratinocyte, with a convoluted nucleus. Its cytoplasm contains vimentin intermediate filaments and small rod- or racket-shaped structures called Langerhans cell granules or Birbeck granules ^[1] | LM EM | H and E CD 1a S-100 Langerin (CD 207) | Are distributed in the epidermis (preference for a suprabasal position), oral cavity, esophagus and vagina. ^[1] They serve as the antigen-processing and presenting cells. ^[1] They are reduced in the epidermis of patients with diseases like psoriasis, sarcoidosis and contact dermatitis, and increased in langerhans cell histiocytosis. |
| Glomus cell | They are large polyhedral cells with a round, centrally located nucleus and a pale eosinophilic cytoplasm. ^[2] The cells are of smooth muscle origin. They comprise of specialized vascular structures called glomus formations. ^[2] These formations have an arterial and venous segment without intervening capillaries | LM EM | H and E Myosin Vimentin | Glomus tumors and glomangiomas arise from the arterial segment of the cutaneous glomus, the Suquet-Hoyer canal. ^[2] Glomus formations are special arteriovenous shunts that appear to play a role in thermoregulation. ^[2] |
| Veil cell | These are flat adventitial cells with distinctive nuclear structure and prominent cytoplasmic processes that surround the dermal microvessels. ^[3] They lie external to the wall, demarcating the vessel from the surrounding dermis. They express factor XIIIa and Von Willebrand factor ^[3] | LM Phase contrast EM | H and E | It is strategically positioned in the organization of the microvessel to participate in the control of bleeding at the microvascular level. ^[4] |

(Continued)

Departments of Dermatology and ²Pathology, St John's Medical College and Hospital, Bangalore, Karnataka, ⁴Department of Dermatology, JN Medical College, Belgaum, India

Address for correspondence: Dr. Fiona F. Sequeira, Department of Dermatology, St John's Medical College and Hospital, Koramangala, Bangalore, Karnataka - 560 034, India. E-mail: dr_fiona@rediffmail.com

| Access this article online | |
|-----------------------------|----------------------------------|
| Quick Response Code: | Website: www.ijdvl.com |
| | DOI: ***** |
| | PMID: ***** |

How to cite this article: Citation will be included before issue gets online***

Received: August, 2011. **Accepted:** November, 2011. **Source of Support:** Nil. **Conflict of Interest:** None declared.

Table 1: (Continued)

| Name | Description/location/size | LM/EM | Stains/markers | Observed in/significance |
|---|--|----------|--|---|
| Mast cell | Are round to spindle in shape with a unilobed round to oval centrally positioned nucleus. Its size varies up to 5–13 μm . They contain in their cytoplasm granules that range from 0.3 to 0.8 μm ^[5] Mast cells synthesize an impressive repertoire of mediators, some of them including histamine, heparin, tryptase, chymase, carboxypeptidase, neutrophil chemotactic factor and eosinophilic chemotactic factor of anaphylaxis ^[5] | LM EM | H and E, Metachromatic staining with toluidine blue, methylene blue, alcian blue and Giemsa: Red-purple, Leder stain, Mast cell tryptase and Chymase CD117 | In the skin, mast cells are present in greatest density in the papillary dermis, near the DEJ, in sheaths of epidermal appendages, and around blood vessels and nerves of the subpapillary plexus. They are also common in the subcutaneous fat ^[1] Activated mast cells are the primary effector cells in the onset of an allergic reaction. They play a role in the defense against parasites, stimulate chemotaxis, activation, and proliferation of eosinophils, promote phagocytosis, alter vasotension and vascular permeability and stimulate connective tissue repair and angiogenesis ^[1] Their numbers are increased in mastocytosis. |
| Tastzellen cells, Merkel cells | Named after the German anatomist Friedrich Sigmund Merkel. These non-keratinocytes are oval in shape, have a pale-staining cytoplasm containing bundles of intermediary filaments and osmiophilic granules. The nucleus is large and lobulated, and the margins of these cells project cytoplasmic “spines” toward the keratinocytes ^[1] | LM EM | Silver impregnation, CAM 5.2 or AE1/AE3, CK 20, Neuron-specific enolase (NSE) | They are found both in hairy skin and in the glabrous skin of the digits, lips, regions of the oral cavity and the outer root sheath of the hair follicle. Merkel cells are slow-adapting, type I mechanoreceptors. Merkel cell carcinoma is a malignant tumor of Merkel cells ^[6] . |
| Tzanck cells/ acantholytic cells/mourning edged cells | It is named after Arnault Tzanck, a French dermatologist. These are large, round keratinocytes with an enlarged hyperchromatic nucleus, hazy or absent nucleoli and abundant basophilic cytoplasm. The basophilic staining is deeper peripherally on the cell membrane (“mourning edged” cells) due to the cytoplasm’s tendency to get condensed at the periphery, leading to a perinuclear halo. ^[7] In contrast to pemphigus vulgaris, the acantholytic cells in pemphigus foliaceus and pemphigus erythematosus often have a hyalinized cytoplasm that corresponds to the dyskeratosis seen in tissue sections | LM | H and E, Giemsa, Papanicolaou stain, Wright, Methylene blue, Toluidine blue | Pemphigus. This is a form of primary acantholysis. The other examples include Darier’s disease, transient acantholytic dermatoses and warty dyskeratoma. When acantholysis occurs secondary to some alteration/damage to epidermal cells, the term secondary acantholysis is used. E.g., bullous impetigo, herpes simplex/zoster and squamous cell carcinoma. |
| Tadpole cells | Are cells with a “tadpole-like” shape. Presence of more than 10 tadpole cells in a Tzanck smear at $\times 100$ magnification is a diagnostic indicator for spongiotic vesicular dermatitis ^[8,9] | LM | H and E | Spongiotic vesicular dermatitis. E.g., allergic contact dermatitis. |
| Gargoyle cells/ Hurler cells | A large oval or polygonal cell, 20 μm in diameter, with a pale central nucleus, the cytoplasm appearing clear on H and E staining. When stained with toluidine blue, metachromatic granules are seen in the cytoplasm. ^[10] On EM, the cytoplasm of the clear cells is seen to be filled with large irregular clear vacuoles varying in size from 0.5 μm to 2 μm . The membranes of the vacuoles are often broken and the ruptured ends curl. Occasionally, mitochondria and cisterns of endoplasmic reticulum are interspersed between the vacuoles | LM EM | H and E, Toluidine blue, Alcian blue | Are seen in Hurler syndrome. |

(Continued)

Table 1: (Continued)

| Name | Description/location/size | LM/EM | Stains/markers | Observed in/significance |
|--------------------------------------|---|----------|---|--|
| Gaucher cells | The disease is named after the French doctor Philippe Gaucher. Gaucher cells are glucocerebroside-laden macrophages measuring 50–60 µm in diameter. On electron microscopy, they contain tubular cytoplasmic inclusions that are considered to be transformed secondary lysosomes. The fibrillar ceramide accumulations are extensive enough to give the cytoplasm a distinctive "crinkled blue tissue paper" appearance ^[11,12] | LM EM | Wright stain, PAS+, Iron stains | Gaucher's disease is an inherited disorder of ceramide metabolism in which an enzyme deficiency leads to the accumulation of glucocerebroside in macrophages of the bone marrow, reticuloendothelial system but not the skin. These cells are not diagnostic of Gaucher disease. Cutaneous manifestation of this condition include patchy pigmentation of the skin and petechiae. |
| Xanthoma cells | Often within the same lesion it's appearance can vary from eosinophilic to clear to foamy or to multinucleated giant cells, which are often referred to as Touton giant cells ^[13] | LM EM | H and E, Fat stains such as oil red O or Sudan black B are required to visualize lipid droplets on frozen sections | Various xanthomatoses, familial hyperlipoproteinemia types IIa, III and V, cerebrotendinous xanthomatosis, Wolman's disease, Tangier disease, Hand-Schuller-Christian disease and normolipidemic cutaneous xanthomatosis. |
| Basalioma cells | Trichoepitheliomas contain an epithelial component composed of uniform small basophilic cells looking like epidermal basal cells with round nuclei and cytoplasm. They are arranged in strands and lobules. They display peripheral palisading and sometimes contain horn cysts or calcifications ^[14,15] | LM | H and E | Trichoepitheliomas, BCC. |
| Basophilic and shadow or ghost cells | Pilomatricomas are sharply demarcated tumors that possess two types of cells: Basophilic cells and eosinophilic shadow cells. The former have round or elongated, deeply basophilic hyperchromatic nuclei and scanty cytoplasm so that nuclei lie close to each other. The latter are anucleate, eosinophilic, keratinized cells having a distinct border and possessing a central unstained area as a shadow of the lost nucleus. These cells frequently calcify ^[16] | LM | H and E | Pilomatricomas. |
| Doughnut cells | They are the intranuclear cytoplasmic inclusions in the large anaplastic mononuclear cells. ^[17] These inclusions are the result of deep cytoplasmic invaginations into the nuclei. Nuclear indentation >70% of the total nuclear diameter is the criterion to term it as a half-doughnut cell ^[18] | LM | H and E Papanicolaou, May-Grunwald, Giemsa, CD30+, Clusterin | Anaplastic large cell lymphoma. |
| Flower cells or clover leaf cells | Are peripheral blood atypical lymphocytes characterized by having irregular nuclear contours, prominent nucleoli, condensed chromatin and deeply basophilic, occasionally vacuolated cytoplasm ^[19] | LM | H and E, CD25+ | Adult T cell lymphoma (ATL) is an aggressive mature T-cell malignancy caused by HTLV-I. It affects the skin in 43–72% of the cases. The disease manifests itself in the skin as erythroderma, plaques, papules, nodules and tumors. ^[20] These so-called flower cells are considered pathognomonic of ATL and are seen in the peripheral blood of these patients. ^[21] |
| Granular cells | Are large polygonal cells in the dermis with distinct cell membranes and prominent eosinophilic granular cytoplasm. The nuclei are usually small, round to oval and centrally located ^[22] | LM | H and E, Granules are PAS+ diastase-resistant | Granular cell tumor, considered to be of peripheral nerve sheath origin can involve various parts of the body (skin and tongue being the most common organs involved). |

(Continued)

Table 1: (Continued)

| Name | Description/location/size | LM/EM | Stains/markers | Observed in/significance |
|--|--|----------|-----------------------------------|---|
| Halo cells | Intraepidermal lymphocytes that are larger than the normal lymphocytes with convoluted, cerebriform nuclei and a clear rim of cytoplasm ^[23] | LM | H and E | Are seen in mycosis fungoides. |
| Hibernoma-like cells, Mulberry cells, multivesicular cells | Are large (average- 54 microns) fat cells containing a central nucleus with a multivacuolated scanty granular, eosinophilic cytoplasm. ^[24] The main histopathologic differentiation of adult adipose tissue from hibernoma cells is the presence of a clear cytoplasm and an eccentric nucleus [Figure 1] | LM | H and E | An uncommon neoplasm derived from brown fat, ^[25] are seen mostly in adults, with a predilection for the thigh, back, axilla, neck and intrathoracic region. |
| Paget cells | Are round or oval cells that appear larger than the keratinocytes. They have a vacuolated amphophilic, cytoplasm with a hypertrophic nucleus, scanty nuclear chromatin and a large nucleolus. No desmosomal attachments are seen between Paget cells and the adjacent keratinocytes ^[26] | LM | H and E, PAS+ | Found in Paget's disease of the breast. |
| Sezary cells, Lutzner cells, Mycosis cell, Cerebriform lymphocytes, Atypia cellulues monstreuses or Monster cell | First described by Albert Sézary. Are atypical lymphocytes with a grooved or cerebriform nucleus. The nuclear chromatin is condensed in a patchy distribution beneath the nuclear membrane. The nucleoli may be prominent. The cytoplasm is sparse and appears as a narrow rim around the nucleus. Mitochondria (often appearing clumped), rough endoplasmic reticulum, polysomes and cytoplasmic fibrils are seen. The cytoplasmic fibrils appear serpentine on electron microscopic examination. The smaller versions of these cells are called Lutzner cells and the larger ones as classical Sezary cells ^[27,28] | LM EM | Wright, Giemsa, PAS | Seen in mycosis fungoides and Sezary syndrome (both in tissue and in blood). |
| Signet ring cells | These cells have a single large vacuole full of mucin. This vacuole displaces the hyperchromatic nucleus to the periphery. ^[29] The pool of mucin in a signet ring cell mimics the appearance of a finger hole, and the nucleus mimics the appearance of the face of the ring in profile [Figure 2] | LM | H and E, Alcian blue, Mucicarmine | Are seen in mucin-producing adenocarcinomas. |
| Spider web cells | Are polygonal or ovoid tumor cells that exhibit cytoplasmic vacuoles due to their glycogen content. Residual strands of cytoplasm between the vacuoles define spider web cells ^[30,31] | LM | H and E | Adult rhabdomyomas. |
| Strap cells | Cells with elongated eosinophilic cytoplasm ^[32] | LM | H and E | Are suggestive but not diagnostic of rhabdomyosarcoma. |
| Reed Sternberg cells | They are named after Dorothy Reed Mendenhall and Carl Sternberg. Are large cells that are either multinucleated or have a bilobed nucleus (resembling an "owl's eye" appearance) with prominent eosinophilic inclusion-like nucleoli ^[33,34] [Figure 3] | LM | H and E, CD30, CD15 | The presence of these cells is pathognomonic for the diagnosis of classical Hodgkin's lymphoma (HL). Other than HL, cells resembling Reed-Sternberg cells may be present in other B and T cell lymphomas, carcinomas, melanomas and sarcomas. The prevalence of skin involvement in HL is approximately 0.5–3.4%. |

(Continued)

Table 1: (Continued)

| Name | Description/location/size | LM/EM | Stains/markers | Observed in/significance |
|--|--|-------|--------------------------------|---|
| Vulvar clear cells of Tokier, intraepidermal glandular cells | Clear cells of Tokier are intraepithelial cells with clear to pale staining cytoplasm and bland cytologic features. They are found in the epidermis of the nipple, immediately adjacent to the openings of the lactiferous ducts, along the basal layer of the epidermis or scattered in the stratum Malpighii. Tokier cells are distributed as single units or as small aggregates that occasionally form small lumina. They have been considered a primitive or germinative cell of the lactiferous duct or interepithelial extension of the lactiferous duct cells ^[35,36] | LM | H and E, CK ₇ , EMA | Found in approximately 10% of normal nipples. Clear cells of Tokier have generated interest as a possible precursor cell of primary intraepidermal extramammary Paget's disease, as morphologically they appear to be a benign counterpart of the malignant cells of Paget's disease. |
| Floret giant cells | These are multinucleated giant cells that have marginal, often overlapping nuclei and an eosinophilic center ^[37] | LM | H and E, Vimentin, CD34 | Seen in pleomorphic lipoma, giant cell collagenoma, giant cell fibroblastoma, giant cell angiofibroma, neurofibromatosis type 1. |
| Touton giant cells | These cells have a peripheral wreath-like arrangement of nuclei, with amphophilic cytoplasm centrally and pale, foamy cytoplasm at the periphery of the cell outside the nuclei ^[38] | LM | H and E | Seen in xanthoma, disseminated xanthoma, juvenile xanthogranuloma, necrobiotic xanthogranuloma and dermatofibroma |
| Hobnail cells | Are plump endothelial cells with scanty cytoplasm and enlarged prominent, hyperchromatic nuclei with one or two minute nucleoli. These endothelial cells are disposed in a monolayer, with nuclei bulging into the vascular lumina, resulting in a characteristic hobnail or matchstick appearance ^[39] | LM | H and E | Hobnail hemangioma is a rare benign vascular tumor. It usually appears as a single, small, well-circumscribed, angiomatous or brownish, flat or exophytic skin lesion. |
| LE cell | The LE cell is the end result of either phagocytosis of distorted nuclear material by a polymorphonuclear leukocyte or autolysis of one or more lobes of the nucleus ^[40,41] The LE cell contains within its cytoplasm the LE body, which appears as a homogenous, pale blue to deep-purplish material pushing the nucleus of the phagocyte to one side of the cell [Figure 4]. | LM | Romanowsky stains | SLE. LE cells are not usually found in peripheral blood, although the LE cell phenomenon could form in the buffy coat of peripheral blood after a period of incubation. |
| Tart cells | A tart cell is a monocyte that has engulfed an intact lymphocyte nucleus. It differs from an LE cell because the secondary nucleus retains its definite chromatin structure ^[40,42] | LM | Romanowsky stains | It is not disease specific. |
| Podophyllin cells | Bizarre, enlarged epithelial cells with either a clumped pyknotic nucleus or with the nuclear chromatin disintegrated and dispersed as small granules throughout the cytoplasm of the cell. These "podophyllin cells" resemble carcinoma cells, but may be distinguished from malignancy by the absence of cytologic atypia and multinucleate giant cells ^[43] | LM | H and E | Seen after the application of podophyllin to normal skin, verruca vulgaris and condylooma accuminata. |
| Mantle cells/ corps ronds | Corps ronds are dykeratotic keratinocytes with a small pyknotic nucleus, acidophilic cytoplasm and a perinuclear halo ("mantle cells") ^[7] . They are seen in the stratum granulosum and upper malpighian layer | LM | H and E | Darier disease. |
| Half and half cells | These are transformed keratinocytes which show increased synthetic activity in one half of the cell, and fibrillar degeneration in the other half of the cell (resembling that of colloid bodies). ^[44] | EM | Phosphotungstic acid | These cells are seen in lichen planus, and are believed to provide a useful clue to the early changes occurring in colloid body formation. |

(Continued)

Table 1: (Continued)

| Name | Description/location/size | LM/EM | Stains/markers | Observed in/significance |
|-------------------------------|---|---------------|----------------------------|--|
| Bean bag cells | They are macrophages that become engorged by phagocytosis of erythrocytes, lymphocytes and cell fragments ^[45] | LM | H and E | Seen in histiocytic cytophagic panniculitis. |
| Sunburn cells | Are pink, dead or dying keratinocytes characteristic of mammalian epidermis after exposure to UVC and UVB radiation or UVA radiation in the presence of psoralens. These cells have a pyknotic nucleus and a shrunken glassy eosinophilic cytoplasm and are seen scattered throughout the epidermis ^[46] | LM | H and E | Seen in sunburns and PUVA-induced acute phototoxicity. |
| Balloon cells | These are polyhedral cells with ample microvesicular cytoplasm, (ultrastructurally corresponding to enlarged vacuolated melanosomes) sparse to absent pigment, distinct cytoplasmic membranes and small, hyperchromatic, round to slightly scalloped central nuclei and rare intranuclear vacuoles or pseudoinclusions ^[47,48] | LM | H and E | Balloon cell nevus. |
| Pekin cells, Reiter cells | Are macrophages 40 µm in size. They contain one or more intact polymorphonuclear leucocytes and deep staining basophilic globular structures within the cytoplasm ^[49] | LM | H and E | In Reiter's disease (50–70% of synovial fluid specimens) as well as any other inflammatory synovial disease. |
| Clue cells | Are squamous epithelial cells with a large number of coccobacillary organisms, <i>Gardnerella vaginalis</i> and other anaerobic bacteria densely attached in clusters to their surfaces, giving them a granular appearance. The cytoplasm appears fuzzy (like shading with black pencil) and the edges of the squamous epithelial cells, which normally have a sharply defined cell border, become indistinct or stippled ^[50] [Figure 5] | LM | Papanicolaou, Gram | Seen in bacterial vaginosis. To be significant for bacterial vaginosis (BV), more than 20% of the epithelial cells on the wet mount should be clue cells. |
| Downey cells/ Turk cells | Named after Hal Downey. Are atypical lymphocytes, which, unlike leukemic cells, show extreme variability of size and shape. They have abundant pale blue cytoplasm. The nucleus may be irregular or indented with lightly stained chromatin. Cytoplasmic edges may be indented by other blood cells, leading to a scalloped appearance called Dutch skirting ^[51-53] | Oil immersion | H and E, Giemsa | Seen in the peripheral blood of infectious mononucleosis patients. The detection of at least 10% atypical lymphocytes on a peripheral blood smear in a patient with mononucleosis has a sensitivity of 75% and a specificity of 92% for the diagnosis of infectious mononucleosis. |
| Greenblatt and Pund cells | Are large mononuclear cells measuring 25–90 µm in diameter. The nucleus of the cell is eccentrically placed, vesicular or pyknotic. There are <20 intracytoplasmic vacuoles containing Donovan bodies in either young non-capsulated or mature capsulated forms ^[54,55] | LM | Giemsa, Leishman, Wright | Seen in granuloma inguinale. |
| Lepra cells/ Virchow cells | Named after Rudolph Virchow. Lepra cells when studied by means of vital staining are found to be derived from the histiocyte of the infected tissue. Their protoplasm, which forms the greater part of the cell, is filled with vacuoles, and contains enormous numbers of lepra bacilli. The nucleus is usually single and is, as a rule, pressed to one side by the vacuoles and bacilli that crowd the cell body. In some instances, these vacuoles are so numerous that there is little actual protoplasm remaining, the cell body having the appearance of a foam. ^[56] In time and with antimycobacterial therapy, degenerate bacilli accumulate in the macrophages, the so-called lepra cells, which then have a foamy or vacuolated cytoplasm [Figure 6] | LM | Modified Fite Faraco stain | They are observed in lepromatous leprosy They resemble xanthoma cells and, on staining with fat stains, are shown to contain lipid, largely neutral fat, and phospholipids rather than cholesterol ^[57] |

(Continued)

Table 1: (Continued)

| Name | Description/location/size | LM/EM | Stains/markers | Observed in/significance |
|-------------------------|--|-------|---|--|
| Mickulicz cells | A large histiocyte measuring 10–100 μm in diameter. It has a pale, vacuolated cytoplasm. Within the cytoplasm of these cells, one finds many <i>Klebsiella bacilli</i> ^[58] | LM | Giemsa, Gram, Warthin-starry silver, PAS+ | The characteristic cell in rhinoscleroma. |
| Von Hansemann cells | Named after David Paul Von Hansemann. Are large macrophages with abundant foamy eosinophilic cytoplasm and a prominent eccentric, hyperchromatic round nucleus. Variable numbers of intracytoplasmic, concentrically laminated, round–ovoid, basophilic inclusions are appreciated and are referred to as Michaelis–Gutmann bodies ^[59] | LM | H and E, PAS-positive, Diastase resistant | Seen in malakoplakia. |
| Langhans giant cells | Named after Theodor Langhans, a German pathologist. They are formed by the fusion of epithelioid cells and contain multiple nuclei arranged in a horseshoe-shaped pattern in the cell periphery or are arranged circumferentially ^[60] | LM | H and E | Seen in tuberculoid granulomas. E.g., tuberculoid leprosy, cutaneous tuberculosis, gumma of syphilis and sporotrichosis. |
| Wright cells | Are large macrophages that contain numerous protozoa grouped together in a typical "swarm of bees" fashion within the weakly basophilic cytoplasm ^[61] | LM | May Grunwald, Giemsa | Seen in cutaneous and mucosal leishmaniasis. |
| Warthin Finkeldey cells | A type of giant cell that vary in size, but can contain as many as 100 nuclei per cell along with cytoplasmic and nuclear inclusions ^[62] | LM | H and E | Pathognomic for measles infection. Found in reticuloendothelial system, exanthem, Koplik spots and respiratory secretions. |
| Koilocytes | Are human papilloma virus-infected vacuolated keratinocytes that bear a basophilic pyknotic nucleus surrounded by a clear halo and pale-staining cytoplasm. They are located in the upper stratum malpighii and in the granular layer. They contain few or no keratohyaline granules ^[63] | LM | H and E | Verruca vulgaris. |
| Mitosoid cells | Are keratinocytes with irregularly shaped hyperchromatic nuclei that simulate mitoses. They are in fact degenerated nuclei without mitotic ability ^[64] | LM | H and E | In focal epithelial hyperplasia (Heck disease). |

LM: Light microscopy, EM: Electron microscopy

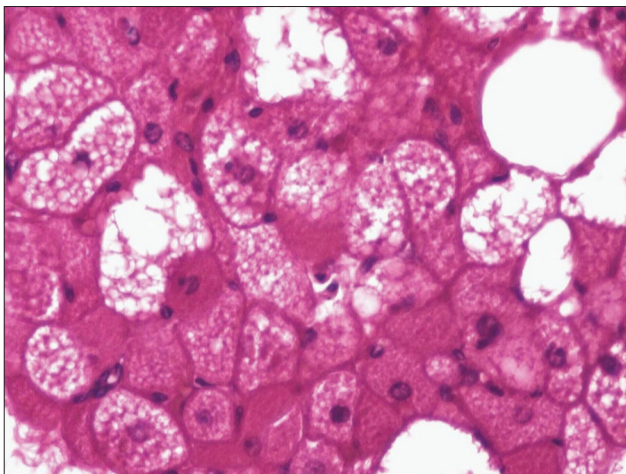


Figure 1: Hibernoma. Large polyhedral fat cells containing eosinophilic granular cytoplasm (x200)

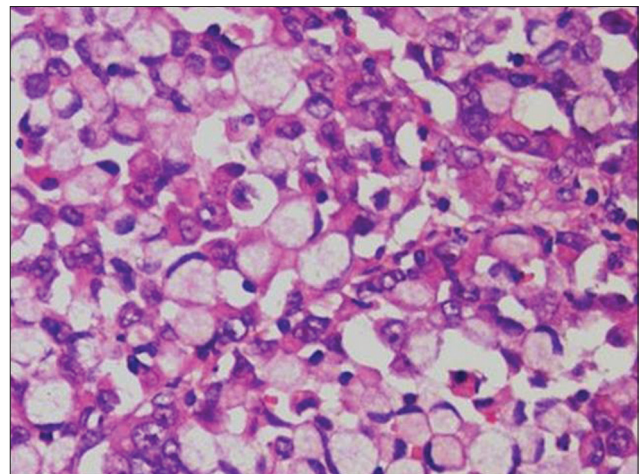


Figure 2: Signet ring cells in an adenocarcinoma. Sheet of large cells with vacuolated cytoplasm pushing the single hyperchromatic nucleus to the periphery (x400)